



Spontaneous closure and reopening of full-thickness macular hole: Two case reports

Chiung-Yi Chiu¹, Yen-Yi Chen², Jia-Kang Wang^{3*}

^{1,2,3} Department of Ophthalmology, Far Eastern Memorial Hospital, New Taipei City, Taiwan

³ Department of Electrical Engineering, Yuan Ze University, Taoyuan City, Taiwan

³ Department of Medicine, National Yang Ming University, Taipei City, Taiwan

³ Department of Healthcare Administration and Department of Nursing, Oriental Institute of Technology, New Taipei City, Taiwan

³ Department of Medicine, National Taiwan University, Taipei City, Taiwan

DOI: <https://doi.org/10.33545/26648520.2019.v1.i1.a.2>

Abstract

Purpose: To present two cases of full-thickness macular hole (FTMH) with spontaneous closure and reopening.

Case reports: The 69-year-old man complained of blurred vision in the right eye. His best corrected visual acuity (BCVA) was 20/800. No significant finding over anterior segment except grade 2 nuclear sclerosis. Fundus examination showed proliferative diabetic retinopathy status post panretinal photocoagulation and macular hole. Optical coherence tomography (OCT) demonstrated a FTMH. The patient underwent outpatient clinic follow up and macular hole spontaneously closure was noted 6 months after first time visit without any surgery. However, OCT revealed no ellipsoid zone recovery and no visual acuity improvement.

The second case is a 52-year-old man. He had high myopia with refractive error of -13 diopters before cataract surgery in the left. He complained of blurred vision of left eye for years. Initial BCVA was 20/100 without significant finding over anterior segment except pseudophakia in the left. Fundus examination revealed myopic FTMH with posterior staphyloma in left eye. OCT demonstrated FTMH with epiretinal membrane. No subretinal fluid or retinal detachment was noted. Closed macular hole was noted after pars plana vitrectomy with epiretinal membrane and internal limiting membrane peeling. His BCVA improved to 20/50. However, closed macular hole reopened to FTMH without associated retinal detachment 4 years later. His BCVA decreased to 20/125 without further management.

Conclusion: Spontaneous closure rate was uncommon in cases with FTMH. BCVA of the first patient remained unchanged even under Hole closure without ellipsoid zone regeneration demonstrated by OCT. Reopening of the hole is one of the complications after initially successful surgery for FTMH and tend to occur in high myopic eyes.

Keywords: spontaneous closure; spontaneous reopening; full-thickness macular hole

Introduction

Full-thickness macular hole (FTMH) is an anatomic defect in the fovea featuring interruption of all neural retinal layers and typically affect females between the sixth and eighth decade of life ^[1]. There is certain percentage of FTMH that close spontaneously ^[2]. Although the anatomic closure in FTMH surgery is achieved in more than 90% of cases. Reopening of the hole is one of the best known complications after initially successful vitreous surgery ^[3]. Herein we will report 2 cases with FTMH having spontaneous closure and reopening of FTMH.

2. Case Reports

The 69-year-old man complained of blurred vision in the right eye. His best corrected visual acuity (BCVA) was 20/800. No significant finding over anterior segment except grade 2 nuclear sclerosis. Fundus examination showed proliferative diabetic retinopathy status post panretinal photocoagulation and macular hole. Optical coherence tomography (OCT) demonstrated a full-thickness macular hole (Figure 1A). The patient underwent outpatient clinic follow up and macular hole gradually closed (Figure 1B) spontaneously.

Totally FTMH closure was noted 6 months after first time visit without any surgery. However, OCT revealed no ellipsoid zone recovery and no visual acuity improvement (Figure 1 C).

The second case is a 52-year-old man with history of diabetes mellitus and hypertension. He had high myopia with refractive error of -13 diopters before cataract surgery in the left. He complained of blurred vision of left eye for years. Initial BCVA was 20/100 without significant finding over anterior segment except pseudophakia in the left. Fundus examination revealed no diabetic retinopathy but a myopic full-thickness macular hole with posterior staphyloma in left eye. OCT demonstrated full-thickness macular hole with epiretinal membrane (Figure 2A). No subretinal fluid or retinal detachment was noted. Closed macular hole was noted after pars planar vitrectomy with epiretinal membrane (ERM) and internal limiting membrane (ILM) peeling 1 month (Figure 2B) and 1 year (Figure 2C) following the surgery. His BCVA improved to 20/50. However, closed macular hole reopened to full-thickness macular hole without associated retinal detachment 4 years later (Figure 2D). His best corrected visual acuity decreased to 20/125 without further management.

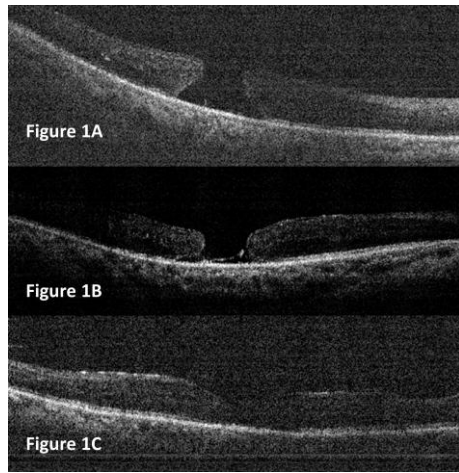


Fig 1: (A) Optical coherence tomography demonstrated a full-thickness macular hole. (B) The macular hole gradually closed spontaneously. (C) The hole complete closure noted 6 months after first time visit without any surgery, but no ellipsoid zone recovery found.

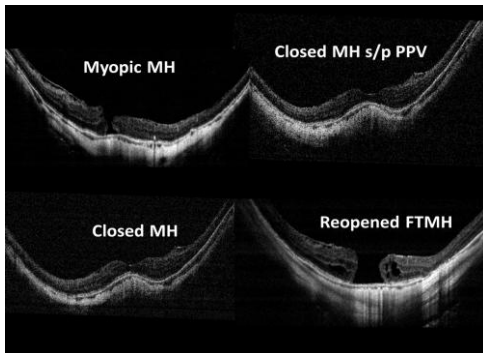


Fig 2: (A) Optical coherence tomography OCT demonstrated full-thickness macular hole with epiretinal membrane. (B) Closed macular hole noted 1 month after the surgery. (C) Closed macular hole noted 1 year after the surgery. (D) Closed macular hole reopened to full-thickness macular hole 4 years later.

3. Discussion

FTMH can be subdivided into idiopathic, or secondary to blunt ocular trauma, high myopia, ERM, or macular edema [4]. The most common type is idiopathic FTMH, developing as a result of abnormal posterior vitreous detachment. As a result of vitreous liquefaction, tangential tractions to the retina, outside to the macula develop and lead to the creation of a FTMH [2, 4]. Our first case was categorized as idiopathic FTMH, and the second one as myopic FTMH coexisting with macular pucker.

There is a certain percentage of FTMH that close spontaneously. Spontaneous FTMH closure rate was previously reported 6.2% and 3.5% [2]. A prior report analyzed the spontaneous closure in 10 eyes of 10 patients with FTMH and found glial cell “bridging” phenomenon was a main mechanism of closure. The average duration of closing was 23.5 weeks. Shorter the duration of symptoms revealed shorter the duration of spontaneous FTMH closure. Connections between inner and outer segments of photoreceptors were rebuilt with better BCVA. In our first case, similar spontaneously bridging process closed the medium-sized FTMH after serial follow-up of macular OCT. Visual acuity did not improve in this case owing to defective ellipsoid zone. Posterior vitreous detachment is not necessary for the FTMH closure.

Surgery of idiopathic FTMH with vitrectomy and ILM peeling is a widely acceptable procedure, with good anatomic and functional results and scarce postoperative complications [5]. Although the anatomic closure in FTMH surgery is achieved in more than 90% of cases. Reopening of the hole is one of the best known complications after initially successful vitreous surgery [3]. Peeling of ILM during primary FTMH surgery is one of the factors that mostly related to reopening, varying between 0% and 8% in eyes with ILM peeling and between 2% and 16% with no peeling [5]. Kumagai *et al.* analyzed the results of surgery in 877 cases of FTMH. The incidence of recurrence was 0.39% in eyes with peeling of ILM, significantly increasing to 7.2% with no peeling ($P < 0.001$) [5]. Besides no peeling, statistically significant risk factors for reopening were myopia of more than 6 diopters and intraoperative retinal tears. Retinal tears treated with laser may be one of the factors that increase the development of ERM, with subsequent tangential traction and reopening of the MH. In our second patient, he did undergo ILM peeling and did not receive retinal laser for retinal breaks. But high myopia and coexisting ERM might be the risk factor for developing reopening of closed FTMH.

In summary, spontaneous closure rate was less than 10% in small or large FTMH. BCVA remained unchanged even under hole closure without ellipsoid zone regeneration demonstrated by OCT. Reopening of the closed hole is one of the best known complications after initially successful surgery and tend to occur in high myopic eyes.

References

1. Ezra E. Idiopathic full thickness macular hole: natural history and pathogenesis. *Br J Ophthalmol*, 2001; 85:102-108.
2. Morawski K, Jędrychowska-Jamborska J, Kubicka-Trzaska A, Romanowska-Dixon B. The Analysis of spontaneous closure mechanisms and regeneration of retinal layers of a full-thickness macular hole: Relationship with visual acuity improvement. *Retina*. 2016; 36(11):2132-2139.
3. Kumagai K, Furukawa M, Ogino N, Larson E. Incidence and factors related to macular hole reopening. *Am J Ophthalmol*, 2010; 149:127-132.
4. La Cour M, Friis J. Macular holes: classification, epidemiology, natural history and treatment. *Acta Ophthalmol Scand*, 2002; 80:579-587.
5. Parravano M, Giansanti F, Eandi CM, Yap YC, Rizzo S, Virgili G, *et al.* Vitrectomy for idiopathic macular hole. *Cochrane Database Syst Rev*. 2015; 12(5):CD009080.