International Journal of Ophthalmology Sciences
www.ophthalmologyjournals.com
Online ISSN: 2664-8539, Print ISSN: 2664-8520
Received: 04-08-2021; Accepted: 21-08-2021; Published: 04-09-2021
Volume 3, Issue 1, 2021, Page No. 09-12

ND: YAG capsulotomy: A review of safety profile and complications at a specialist eye clinic in south-east Nigeria

Anya Kalu[1*], Olufunmi A I Otuka[1], Lisa Eweputanna[2], Joseph Ume K[3], Kennedy Nwachukwu[4], Echieh Chigozie I[4]
[1] Ophthalmology Unit, Department of Surgery, Abia State University Teaching Hospital, Aba, Nigeria
[2] Department of Radiology, Abia State University Teaching Hospital, Aba, Nigeria
[3] Department of Ophthalmology, Alex Ekwueme Federal University Teaching Hospital, Abakaliki, Nigeria
[4] Department of Ophthalmology, University of Calabar Teaching Hospital, Calabar, Nigeria

DOI: https://doi.org/10.33545/26648520.2021.v3.i1a.21

Abstract
Background: Posterior capsule opacification (PCO) is the commonest delayed complication of cataract surgery. It is easily treated by ND YAG Laser posterior capsulotomy, which is associated with a number of documented complications.
Methods: A retrospective review of the cases of ND YAG Laser posterior capsulotomy performed in Anya Specialist Eye Clinic Umuahia, Abia State from March 2019 to June 2021 was done to evaluate safety and complications.
Results: Three hundred and twenty eight (328) eyes of 312 patients were found and included in the study. There were 186 females (59.6%) and 126 males (40.4%) with age range 33 to 80 years, and a mean age of 57.6 years. Complications were observed in 132 patients (40.3%) and included transient rise in intraocular pressure (22.9%), mild uveitis (8.5%), pitting of the IOL (4.9%), radial extension of the capsulotomy (3.4%); with one out of 11 eyes with radial extension developing a vitreous prolapse in the anterior chamber. Intraocular lens tilt was documented in one patient (0.3%) and one patient was observed with hair-line hyphema (0.3%) following an inadvertent hit on the iris.
Conclusion: The complications of ND YAG Laser posterior capsulotomy after PCO are mostly mild and can be easily managed. It is important to be aware of the possible complications in order to prevent them where possible and manage them promptly to avoid long-term visual loss.

Keywords: posterior capsule opacity, ND YAG laser, posterior capsulotomy, laser, eye polishing

Introduction
Cataract is the opacification of the crystalline lens. It causes about half of all cases of blindness and 33% of visual impairment worldwide [1]. The Nigeria National Blindness survey reported that cataract was the most common cause of severe visual impairment and blindness with a prevalence of 45.3% and 43% respectively. The treatment for cataract is surgical, with more than 9.5 million cataract surgeries performed annually worldwide [2]. Cataract surgeries are not without complications. The most common delayed complication is Posterior Capsular Opacification (PCO), which is also known as 'After Cataract' [3]. PCO is caused by the proliferation of lens epithelial cells that have remained within the capsular bag following cataract extraction [4]. This causes fibrotic changes and wrinkling of the posterior capsule [5]. PCO usually presents with decreased vision, glare, and other symptoms similar to that of the original cataract, with its reported frequency ranging from 8.7% to 33.4% [6, 8]. Nd: YAG laser posterior capsulotomy is a relatively noninvasive procedure that is used in the treatment of PCO [9]. It was first presented by Drs. Aron-Rosa and Fankhauser in the early 1980s [10, 11]. and has since then showed itself to be an effective alternative to the surgical treatment of PCO, thereby avoiding such complications as endophthalmitis and vitreous loss [12, 13]. Nd-YAG laser posterior capsulotomy applies a series of focal ablations, thereby causing photodisruption of the thickened posterior capsule and creating a small circular opening in the visual axis [14].
Prior to the procedure, the patient's visual function is assessed with their physiological pupil state for the best corrected distant and near visual acuity using visual charts. The eye is then adequately dilated in order to visualize the PCO properly. Topical anesthesia is then instilled into the eye, followed by a pretreatment with topical 0.5% timolol, to prophylactically prevent an elevation in the intraocular pressure (IOP). Patient is then positioned on a slit lamp equipped with Nd: YAG laser for the procedure.
Safe and successful laser capsulotomy involves accurate focusing and use of the minimum energy required [4]. The laser power is most times set at lowest possible MJ/pulse, and increased if necessary. Some research suggest that the total energy applied should be less than 80mj, in order to reduce risk of significant IOP spikes or increase in macular thickness [4]. Capsulotomies should equate approximately the size of the physiologically dilated pupil under scotopic conditions, which is about 4mm-5mm in the pseudophakic eye [4]. However, small capsulotomies (2-3mm) have been found to be equally as effective as large capsulotomies (5-6mm), although larger capsulotomies may be more helpful for patients with symptomatic glare [4]. Some of the techniques for Nd: YAG laser delivery includes cruciate, circular, horseshoe and spiral techniques [4].
The major indication for Nd: YAG laser capsulotomy has remained posterior capsule opacity, which would usually present with decreased vision, glare, and difficulty in visualizing the fundus [2]. However, there are certain contraindications to the use of Nd: YAG laser for capsulotomy, which includes corneal scarring or edema that prevents a clear view during the procedure; presence of a glass intraocular lens (IOL) in the eye; presence of uveitis, macular edema or a history of retinal tear or detachment. It is also contraindicated in the immediate postoperative period, as the IOL may not have been adequately scarred into place. Also, in patients with glaucoma who may be at risk of intraocular pressure spike from the inflammation of the procedure, or from post procedure steroid response [15, 16]. Documented complications of Nd: YAG laser

capsulotomy include rise in intraocular pressure, uveitis, IOL subluxation or dislocation, IOL pitting, vitreous prolapse, floaters, retinal tear & detachment and macular oedema [8, 11, 17, 19]. The purpose of this study is to review the safety and complications of Nd: YAG laser capsulotomy at the Anya Specialist Eye Clinic, Umuahia, Abia State Nigeria, with the aim of improving quality and safety of Nd: YAG laser services in the center.

Methodology

This is a retrospective review of 312 patients (328 eyes) that underwent Nd: YAG laser posterior capsulotomy after cataract surgery with posterior chamber IOL implantation at the Anya Specialist Eye Clinic, Umuahia, Abia State Nigeria, between March 2019 to June 2021. The indication for the procedure was posterior capsule opacity after cataract surgery. For this procedure, a pre YAG laser best corrected visual acuity, IOP, anterior and posterior segment examination with slit lamp and indirect ophthalmoscopy were carried out. B-scan ultrasound was done in 4 patients prior to Nd: YAG laser capsulotomy.

Patients were adequately counseled on the procedure and the possible side effects, and consent was gotten. Topical anesthesia with 0.5% proparacaine was given, with subsequent pupillary dilatation with 1% tropicamide and or 5% Phenylephrine hydrochloride in order to properly visualize the PCO. After proper positioning of the patient on a slit lamp equipped with Nd: YAG laser, pulses of laser were delivered in a single pulse mode of initial power of 1.5mj/pulse and gradually increased. Laser delivery was routinely done in a circular fashion within the central 3mm, avoiding the centre. Total energy applied was usually targeted at 50mj or less. Few cases had total energy more 80mj. Post Nd: YAG laser capsulotomy, topical anti-inflammatory and pressure lowering agents were given. Patients were routinely reviewed two weeks post procedure and the ophthalmological findings were documented.

Results

Of the 312 patients (328 eyes), 59.6%(186) were females and 40.4% (126) were males. The age ranged from 33 to 80 years, with a mean age of 57.6 years.

The Nd: YAG Laser was effective in clearing the central 3mm of the visual axis, and none of the patients required a retreatment with the Nd: YAG laser.

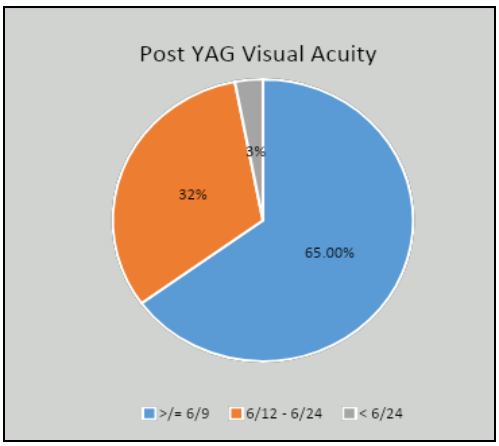

Fig 1: Post ND: YAG laser visual acuity

The pie chart above shows that of the 328 eyes, 65% (213 eyes) had a post-laser best corrected visual acuity (BCVA) of 6/9 or better, at follow up visit. Thirty-two percent (105 eyes) had a BCVA of 6/24 to 6/12, while 3% (10 eyes) had a BCVA less than 6/24.

Table 1: Complications of Nd: YAG capsulotomy

Complications	No. of cases	Percentage
Transient rise in IOP	75	22.9%
Anterior Uveitis	28	8.5%
IOL Pitting	16	4.9%
Radial extension of capsulotomy	11	3.4%
Hyphema	1	0.3%
IOL tilt	1	0.3%
Total	132	40.3%

Complications were seen in 132 cases (40.3%), while 196 cases (59.7%) had no complications. Table 1 shows the complications observed. They include a transient rise in intraocular pressure measured within the first 3 hours post Nd: YAG, which was seen in 22.9% (75 eyes). With the use of pressure lowering medications (0.5% timolol), at 2 weeks post YAG review, IOP was noted to have returned to pre procedure levels. Mild uveitis was seen 8.5% (28 eyes). Pitting of the IOL occurred in 4.9% (16 eyes), while radial extension of the capsulotomy was observed in 3.4% (11 eyes), out of which one of the patient had vitreous prolapse into the anterior chamber. The patient subsequently had an anterior vitrectomy, and vision was restored to a line less than the pre YAG Laser capsulotomy visual acuity.

Other complications documented were hyphema (hairline) in one eye which occurred after an inadvertent hit on the iris. One case of IOL tilt was also documented.

Discussion/Recommendations

Nd: YAG laser capsulotomy has proven to be an effective way of managing PCO with favorable visual outcome. Although it is noninvasive and considered safer than surgical approach, it carries the risk of some complications. It is therefore vital to have a knowledge of the possible complications, so as to prevent and also manage them accordingly.

Out of the 328 cases, complications were seen in 132 cases (40.3%), while 196 cases (59.7%) had no complications. In a similar study, Ajite *et al* found complications in 21.1%, while 78.9% were without complications [20].

The most common complication observed in our study was a rise in intraocular pressure, which occurred in 22.9%. This was also the most common complication observed by Ajite *et al* (10%) [20]. Different explanations which have been given for the pressure rise include the deposition of debris in the trabecular meshwork, pupillary block and inflammatory swelling of the ciliary body or iris root [19, 21, 23].

Despite prophylactic treatment with 0.5% Timolol, increased IOP was reported in 15% to 30% of patients in several studies [24, 25]. Ge *et al* found that the rise in IOP was more pronounced in patients with glaucoma. However, Shani *et al* could not find any elevation of IOP, and postulated that healthy pseudophakic eyes do not show an elevation of IOP after Nd: YAG laser capsulotomy [26, 27].

Mild uveitis was seen in 8.5%, which was transient and resolved with the application of topical steroid (0.1% dexamethasone), leaving no delayed complication. A study by Gore *et al* [28] reported that 33.5% patients had iritis, which manifested as cells and flare in the anterior chamber on slit lamp examination.

Pitting of IOL was observed in 4.9% of cases. A similar study by Hassan KS *et al* [29] noted IOL pitting of 19.8% in a study of 86 eyes, while Haris WS [30] noted significant marks on the IOL in 11.7% during laser capsulotomy in 342

eyes. It's been noted that retro-focusing of laser aiming beam can reduce the risk of IOL damage.

Radial extension of the capsulotomy was observed in 3.4%, out of which one of the patient had a vitreous prolapse. Cases of vitreous prolapse following Nd: YAG laser capsulotomy have been documented, and has been said to occur when the capsulotomy goes beyond the circumference of the IOL optic [4]. Ajite *et al* observed vitreous in the anterior chamber in 2.2% of cases [20]. Also, a case of IOL tilt was documented, although there was no associated hyperopic shift. There has been several reports of displaced IOLs [31, 32].

Levy *et al* reported two instances of IOL dislocation into the vitreous following Nd: YAG laser capsulotomy. Its occurrence was found to be higher in larger capsulotomy opening than small capsulotomy openings [31].

There was no documented case of retinal tear & detachment, although studies have shown that the risk of retinal detachment (RD) after Nd: YAG laser capsulotomy is estimated to be 4-fold that of the risk after an uneventful cataract excision surgery without Nd: YAG laser capsulotomy [33, 34].

There has also been reported cases of cystoid macular edema (CME) which wasn't documented in our study. A study by Lewis *et al* [33] found a low rate of CME when Nd: YAG laser capsulotomy was delayed for over 6 months from the initial IOL implant date [35]. A study by Ari *et al* found out that the rate of CME in patients treated with high energy levels were significantly greater compared to those treated with low energy levels, while another study found no significant difference between rate of CME occurrence and energy level used in Nd: YAG laser Capsulotomy [36, 37].

Conclusion

Improvement of visual acuity after Nd: YAG laser capsulotomy is excellent. Its complications are minimal and usually transient and could be minimized by using low energy pulses, as well as aiming for small openings of 2-3mm. It is therefore a safe method of restoring vision in patients with posterior capsule opacification.

References

1. Global Data on Visual Impairment; 2010 (PDF). WHO, 2012, 6
2. Foster A. Vision: the cataract challenge. Community Eye Health,2000:13:17-9.
3. Wormstone IM. Posterior capsular Opacification: a cell biological perspective. Exp Eye Res,2002:74:337-347.
4. Brad B. Kanski's Clinical Ophthalmology: Management of age-related cataract. Eight edition, 2016, 293-294.
5. Oner FH, Gunenc U, Ferliel ST. Posterior capsule Opacification after phacoemulsification: foldable acrylic versus poly intraocular lenses. J cataract refract surgery,2000:26(5):722-6.
6. Knorz MC, Soltau JB. Incidence of posterior capsule Opacification after extracapsular cataract extraction in diabetic patients. Metab pediatr syst Ophthalmol,1991:14(3-4):57-8.
7. Awan MT, Khan MA, Al-Khairy S, Malik S. Improvement of visual acuity in diabetic and nondiabetic patients after Nd: YAG LASER Capsulotomy. Clin Ophthalmol,2013:7:2011-7.
8. Ari S, Cingu AK, Sahin A, Cinar Y, Caca I. The effects of Nd: YAG LASER Capsulotomy on macular thickness, intraocular pressure and visual acuity. Ophthalmic Surg Lasers Imaging,2012:43(5):395-400.
9. Aslam TM, Patton N. Methods of assessment of patients for Nd: YAG LASER Capsulotomy that correlate with final visual improvement. BMC Ophthalmol,2004:23:4:13.
10. Aron-Rosa D, Aron JJ, Griesemann M, Thyzel R. Use of the neodymium-YAG laser to open the posterior capsule after lens implant surgery: a preliminary report. J Am Intraocular Implant Soc,1980:6(4):352-4. PMID: 7440377.
11. Fankhauser F, Roussel P, Steffen J. Clinical studies on the effectivity of high power laser radiation upon some structures of the anterior segment of the eye. First experiences of the treatment of some pathological conditions of the anterior segment of the human eye by means of a Qswitched. Int Ophthalmol,1981:3(3):129-39. PMID: 7196390.
12. Shah GR, Gills JP, Durham DG, Ausmus WH. Three thousand YAG lasers in posterior Capsulotomies: an analysis of complications and comparison to polishing and surgical decision. Ophthalmic Surg,1986:17(8):473-7. PMID: 3748538.
13. Chambless WS. Neodymium: YAG laser posterior Capsulotomies results and complications. J Am Intraocul Implant Soc,1985:11(1):31-2. PMID: 3838167.
14. Smith RT, Moscoso WE, Trokel S, Auran J. The barrier function in neodymium-YAG laser Capsulotomy. Arch Ophthalmol,1995:113(5):645-652.
15. Fan DS, Lam DS, Li KK. Retinal complications after cataract extraction in patients with high myopia. Ophthalmology discussion 691-2,1999:106(4):688-91.
16. Barnes EA, Murdoch IE, Subramaniam S, Cahill A, Kehoe B, Behrend M. Neodymium:YAG Capsulotomy and intraocular pressure in pseudophakic patients with glaucoma. Ophthalmology,2004:111(7):1393-7.
17. Keates RH, Steinert RF, Puliafito CA, Maxwell SK. Long-term follow-up of Nd: YAG LASER Capsulotomy. J Am Intraocul Implant Soc Spring,1984:10(2):164-8. PMID: 6547424.
18. Parker MD, Clofeine GS, Stocklin RD. Marked intraocular pressure rise following Nd-YAG laser Capsulotomy. Ophthalmic Surg,1984:15(2):103-4. PMID:6546789
19. Gore VS. The study of complications of Nd: YAG LASER Capsulotomy. Klin Monbl Augenheilkd,1994:204(5):286-7. PMID: 8051851.
20. Ajite KO, Ajayi IA, Omotoye OJ, Fadamiro CO. Visual Outcome of Patients with Posterior Capsular Opacification treated with Nd: YAG Laser. Journal of Medicine and Medical Research,2013:1(4):23-27.
21. Vine AK. Ocular hypertension following Nd: YAG LASER Capsulotomy: A potentially blinding complication. Ophthalmic Surg,1984:15(4):283-4. PMID: 6547221.
22. Parker MD, Clofeine GS, Stocklin RD. Marked intraocular rise following Nd: YAG LASER Capsulotomy. Ophthalmic Surg,1984:15(2):103-4. PMID:6546789.
23. Ruderman JM, Mitchell PG, Kraff M. Pupillary block following Nd: YAG LASER Capsulotomy. Ophthalmic Surg,1983:14(5):418-9. PMID: 6877743.

24. MacEwen CJ, Dutton GN, Holding D. Angle closure following Nd: YAG LASER Capsulotomy in the aphakic eye. Br J Ophthalmol,1985:69(10):795-6. PMID 3840385.
25. Minello AAP, Prata JA, de Arruda Mello PA. Efficacy of topical hypotensive agents after posterior Capsulotomy. Arquivos Brasileiros de Oftalmologia,2008:5:706-710.
26. Lin JC, Katz LJ, Spaeth GL, Klancnik JM. Intraocular control after Nd: YAG LASER Capsulotomy in eyes with glaucoma. Arq Bras Oftalmol,2008:71(5):706-10. PMID: 19039468.
27. Ge J, Wand M, Chiang R, Paranhos A, Shields B. Long term effect of Nd: YAG LASER Capsulotomy on intraocular pressure. Arch Ophthalmol,2000:118(10):1334-7. PMID: 11030814.
28. Mahtab Alam Khanzada, Shafi Muhammad Jatoi, Ashok Kumar Narsani, Syed Asher Dabir, Siddiqa Gul. Is the Nd: YAG Laser a safe procedure for posterior Capsulotomy? Pak J Ophthalmol,2008:24:73-78.
29. Hassan KS, Adhi MI, Aziz M *et al*. Nd: YAG Laser Posterior Capsulotomy. Pak J Ophthalmol,1996:12:3-7.
30. Harris WS, Herman WK, Fagadau WR. Management of the posterior capsule before and after the YAG laser. Trans Ophthalmol Soc UK,1985:104(5):533-5. PMID: 3863342
31. Levy JH, Pisacano AM, Anello RD. Displacement of bagplaced hydrogel lenses into the vitreous following Nd: YAG LASER Capsulotomy. J Cataract Refract Surg,1990:16(5):563-6. PMID: 2231370.
32. Maguire AM, Blumenkranz MS, Ward TG, Winkelman JZ. Scleral loop fixation for posterior dislocated intraocular lenses. Arch Ophthalmol,1991:109(12):1754-8. PMID: 1841589
33. Lewis H, Singer TR, Hanscom TA, Straatsma BR. A prospective study of cystoid macular edema after Nd: YAG LASER Capsulotomy. Ophthalmology,1987:94(5):478-82. PMID: 3601362.
34. Tielsch JM, Legro MW, Cassard SD *et al*. Risk factors for retinal detachment after cataract surgery. A population based study. Ophthalmology,1996:103(10):1537-45. PMID: 8874424.
35. Giocanti-Aure'gan A, Tilleul J, Rohart C *et al*. OCT measurement of the impact of Nd: YAG LASER Capsulotomy on foveal thickness. J Fr Ophthalmol,2011:34(9):641-6. Doi:10.1016/j.jfo.2011.02.020. PMID: 21889816.
36. Ari S, Cingu AK, Sahin A, Inar YC, Caca I. The effects of Nd: YAG LASER Capsulotomy on macular thickness, intraocular pressure, and visual acuity. Ophthalmic Surg Lasers Imaging,2012:43(5):395-400. doi:10.3928/15428877-2012070-03. PMID: 22785102.
37. Karahan E, Tuncer I, Zengin MO. The effect of Nd: YAG LASER Capsulotomy size on refraction, intraocular pressure and macular thickness. J Ophthalmol. PMID: 24724016.